What does it mean when a child is diagnosed with pneumonia?

Miles Weinberger MD

Professor Emeritus, University of Iowa

Visiting Clinical Professor of Pediatrics, University of California San Diego,

Rady Children's Hospital

Abstract

Pneumonia is a frequent diagnosis without adequate consideration of the etiology. Pneumonia implies the presence of inflammation of the lung parenchyma with consolidation. That inflammation may be from infectious or non-infectious causes. Radiologic diagnosis of pneumonia is subject to inter-observer interpretation and may misdiagnose non-inflammatory radiologic opacifications as pneumonia. The common diagnosis of community acquired pneumonia in children most commonly has a viral rather than bacterial etiology. Antibiotics should be reserved from those where the clinical course, laboratory measure of biomarkers, and the radiology are consistent with the diagnosis of pyogenic bacterial pneumonia.

Cases with a Diagnosis of Pneumonia

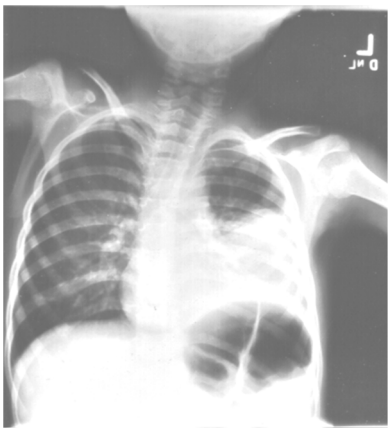

Case number 1) An 8-year-old boy presents with acute onset fever and left sided chest pain. He appears toxic and has rapid breathing. There are mild intercostal retractions, but no supra-or sub-sternal retractions. There are diminished breath sounds on the left.

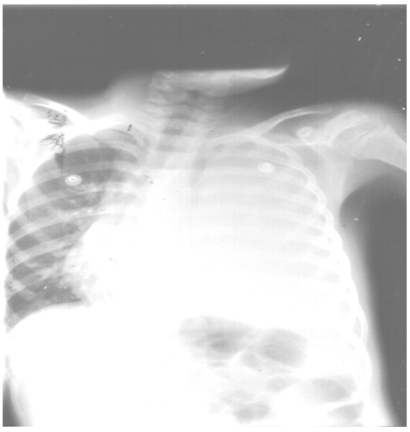

He is treated with antibiotics. One week later his x-ray looks worse and he is still febrile

Diagnosis: Pyogenic pneumonia (most commonly Streptococcus pneumoniae) complicated by a parapneumonic pleural effusion.

Comment: This is a typical clinical course of Streptococcus pneumonia exhibiting rapid onset of high fever, toxic appearance, and tachypnea but respiration is not usually labored. There is a risk of fatality if not treated with an antibiotic to which the organism is sensitive. The fever may initially improve from the antibiotic, and the patient may become less toxic in appearance prior to return of fever and increased radiologic opacification. This indicates a parapneumonic effusion. Although a parapneumonic effusion can be associated with fever, it is generally not infected and can eventually resolve on its own. A diagnostic tap can sample the fluid and determine if there is infection. If substantial mediastinal shift with increasing respiratory distress from compression of the right lung occurs, removal of the fluid may become necessary.

Case number 2) An 8-year-old. girl presents with cough, low grade fever, malaise, and sore throat for a week. She is alert and in no major distress.

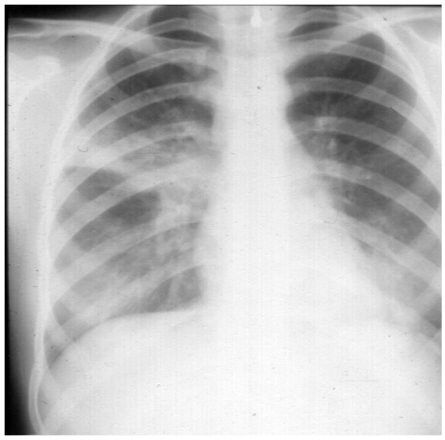

Diagnosis: Mycoplasma pneumoniae

Comment: This is a classic example of pneumonia from Mycoplasma pneumoniae. While this will resolve on its own, more rapid improvement may occur from use of a macrolide antibiotic.

Case number 3) A 6-year-old. girl presents with worsening cough for the past 2 days. It was preceded by rhinorrhea with an initial low grade fever 3 days ago. She is now afebrile and not toxic appearing, but she is having labored breathing. She has had multiple prior similar episodes, many diagnosed as pneumonia. She has intercostal, supra-and sub-sternal retractions. She has decreased breath sounds throughout but no localizing signs**.**

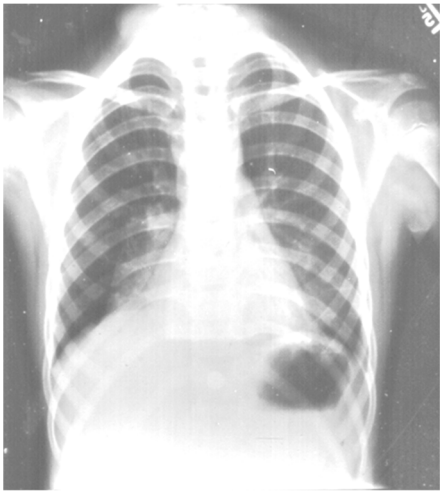

Diagnosis: Viral respiratory infection induced asthma exacerbation manifested by hyperinflation and patchy right middle lobe atelectasis.

Comment: This is a common presentation of a young child with an asthma phenotype characterized by recurrent exacerbations of asthma initiated by a common cold viral infection, rhinovirus being the most common. Wheezing may absent where there is severe airway obstruction. Treatment with a bronchodilator aerosol will provide some short-term relief of symptoms, but a short course of an oral corticosteroid is important to stop progression and shorten the course. Antibiotics are not indicated.

Case number 4) A 3-year-old boy presents with tachypnea and cyanosis for several weeks with gradual worsening. He is afebrile, has mild intercostal, but no supra- or sub-sternal retractions. Pulse oximeter reads 80%, arterial blood pCO_2 is 30 mmHG.

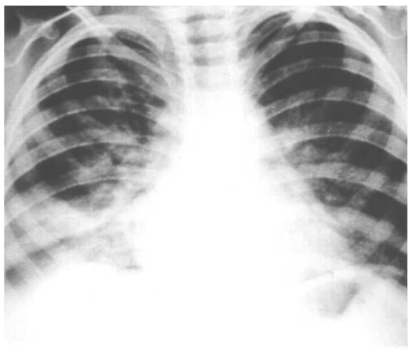



Additional history identifies pink doves (a type of pigeon) raised in the front room of his house.

Diagnosis: Pigeon breeder's lung disease, an allergic alveolitis.[1]

Comment: Ouchterlony double gel diffusion identifies precipitins to pigeon serum antigen. Treatment requires avoiding pigeon exposure. He improved slowly to normal physiology once no longer exposed to pigeons. Continuous or repeated exposure may cause pulmonary fibrosis.

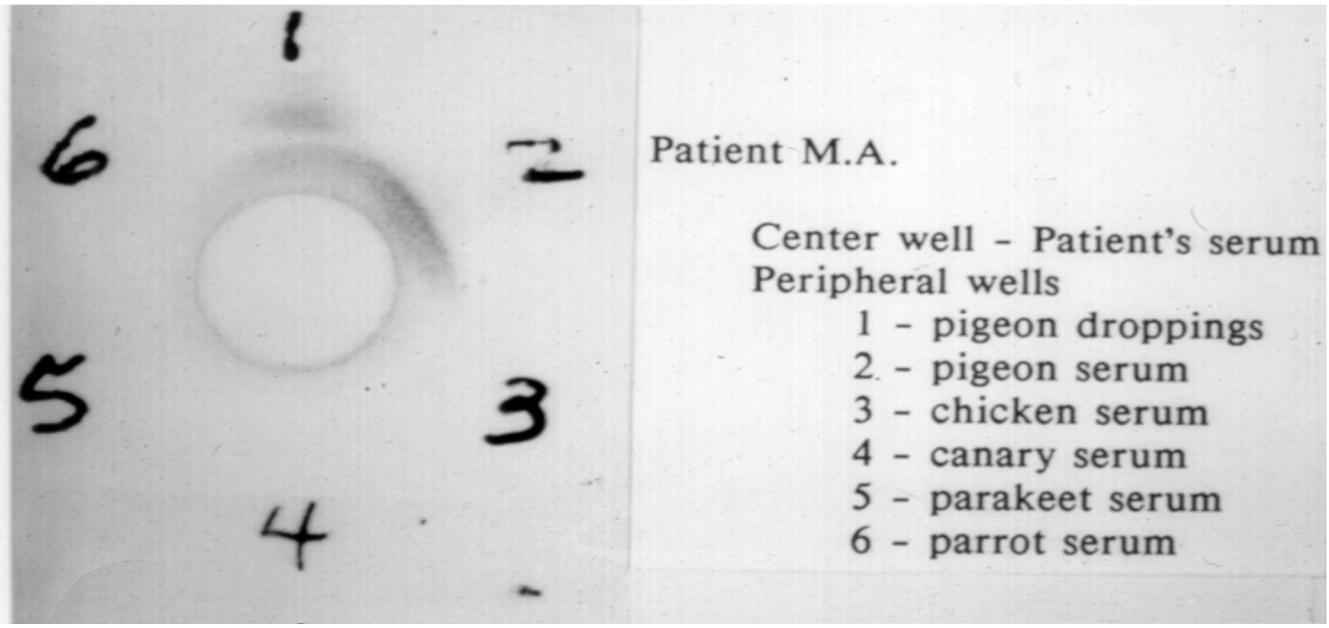

Case number 5) Healthy infant had this chest film taken during a febrile illness that subsequently self-resolved.

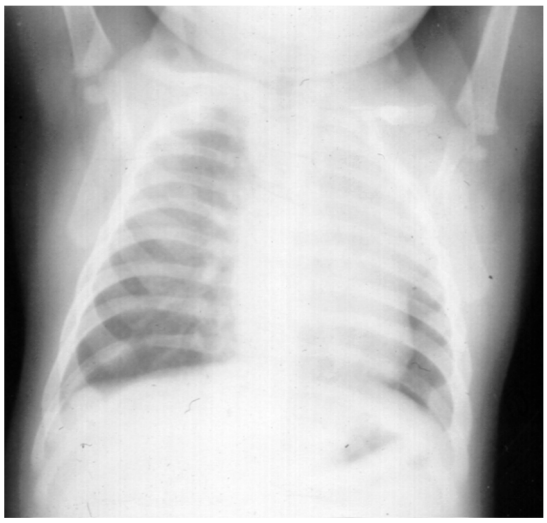

Diagnosis: A chest CT identified right upper lobe agenesis.

Comment: This is an example of a pseudo-pneumonia. No treatment is indicated. Disability is unlikely in the absence of other abnormalities.

Case number 6)) Healthy infant who had this chest film taken during a period of prolonged cough that subsequently self-resolved.

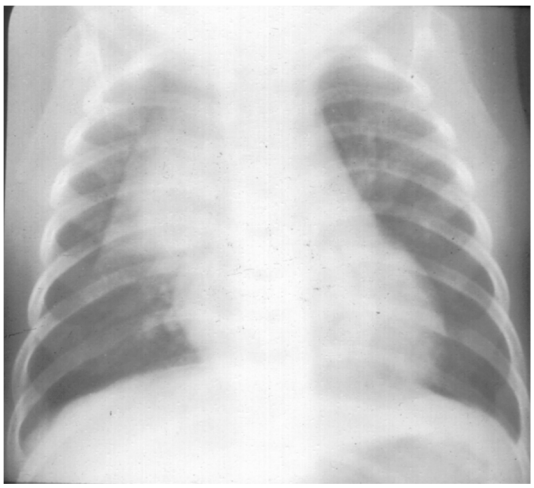

Diagnosis: This is thymus exhibiting a classic "sail sign." Another potential pseudo-pneumonia

Comment: The thymus may be a visible part of the mediastinum in infants. The radiologic shadow can vary and occasionally requires a chest CT scan to distinguish it from a pathologic mediastinal shadow. While older literature attributed the thymus as a cause of respiratory distress under the diagnostic name of "thymus status lymphaticus."[2] That diagnosis has long since been discarded.

91 **What is "pneumonia"?**

92 The first 4 of the cases presented above illustrate different clinical processes that are all called
93 pneumonia. Case number 1 is a classic bacterial pneumonia requiring urgent antibiotic treatment. A
94 parapneumonic effusion can occur even when appropriate antibiotic treatment is provided. Case
95 number 2 is a typical clinical course of what used to be called atypical pneumonia that we know now is
96 generally caused by Mycoplasma pneumoniae. Case 3 is an example of an allergic pneumonia, in this
97 case from exposure to pigeon antigen. Case 4 illustrates a child with recurrent inflammation of the
98 airways from various common cold viruses, a characteristic of a common asthma phenotype. The
99 resulting mucous secretions can obstruct airways causing atelectasis as air is absorbed beyond the site
100 of obstruction. The resulting opacities are then frequently misdiagnosed as pneumonia. Cases 5 and 6
101 illustrate opacities unrelated to any disease process that may initially be misdiagnosed as pneumonia.

102 These cases illustrate that the inflammatory process that results in pneumonia includes
103 different forms of pathology. The inflammation may or may not be from infection, and infection, when
104 present, may or may not be bacterial and susceptible to antibiotics. Meaningful diagnosis with
105 treatment implications requires an adjective preceding the word pneumonia, bacterial, Mycoplasma,
106 viral, allergic.

107 Therefore, there are many pneumonias. In addition to acute pneumonias there are
108 chronic pneumonias, and pneumonias not caused by an infectious agent. Pneumonias can be
109 described in terms of anatomical location or epidemiological characteristics (table 1). While
110 that descriptive term may have some utility in suspecting etiology and deciding on initial
111 treatment, a specific etiology is more useful for providing the most specific treatment (table
112 2).

113

114 **What causes pneumonia?**

115 A common diagnosis is "community-acquired pneumonia." That is defined as an acute
116 infection of the pulmonary parenchyma in a patient who has acquired the infection in the community.
117 For children, this essentially includes any previously healthy child where a diagnosis of pneumonia is
118 made. A comprehensive assessment of the etiology of children with community-acquired
119 pneumonia requiring hospitalization was performed at 3 hospitals in different major U.S.
120 cities.[3] A viral or bacterial pathogen was identified in 81% of 2222 children with
121 radiographic evidence of pneumonia. The radiographic evidence varied. Descriptions
122 included the presence of consolidation (58%), linear and patchy alveolar or interstitial
123 densities (51%), or pleural effusion (13%). Forty-five percent of the children were less than 2
124 years of age and 25% were ages 2 to 4 years. Interestingly, 33% had asthma or asthma-like
125 symptoms (see Case number 3). At all ages, viral pathogens were identified as the major
126 etiology associated with pneumonia in those children (Figure 1).

127 Respiratory Syncytial Virus (RSV) was the most common isolate in children less than
128 4 years of age and continued to be identified in older children. Human rhinovirus was the
129 second most common isolate, only somewhat less frequent than RSV in children under 4
130 years of age, Rhinovirus was the most common isolate in the 5 to 9-year-old group, second in
131 frequency only to Mycoplasma pneumoniae in those 10 to 17 years old. Mycoplasma
132 pneumoniae became an increasing etiology of pneumonia with age. Streptococcus
133 pneumonia, the most serious etiology, made up a small fraction of pneumonia at all ages.

134

135 **Diagnosing pneumonia**

136 The diagnosis of pneumonia is commonly made or confirmed radiologically. While
137 consolidation can certainly be seen radiologically, the best radiograms with the best
138 radiologists cannot identify inflammatory cells in the lung parenchyma, nor can the various
139 etiologic agents be distinguished. A chest x-ray is essentially a shadowgram. Areas of
140 localized atelectasis and anatomical anomalies may all result in opacities that could be
141 misinterpreted as a pneumonic infiltrate (Table 3).

142 Moreover, there is a degree of subjectivity involved in the interpretation of chest x-
143 rays. In an evaluation of the World Health Organization criteria for diagnosing pneumonia
144 from a radiograph, this subjectivity was apparent in the lack of uniformity in interpretation,
145 particularly for patchy and perihilar changes.[4,5] It is among children under age 6, the age with
146 the highest frequency of pneumonia diagnoses, that the radiologic interpretation is most
147 likely to suffer from such variability in interpretation. A critical commentary on chest
148 radiographs for childhood pneumonia agreed that a negative chest film, i.e., the absence of
149 consolidation, excludes pneumonia, but the presence of areas of consolidation alone should not dictate
150 treatment.[6]

151 Over-diagnosing of pneumonia is common, especially among children under age 6. At
152 a university hospital outpatient clinic in Turkey, 126 children diagnosed as pneumonia and
153 prescribed antibiotics were subsequently reevaluated in a Pediatric Chest Disease Department
154 of the same hospital.[7] That reevaluation determined that the diagnosis of pneumonia was not
155 supported in 40% of the patients, and antibiotics were judged to be unnecessary in 85%. An
156 observational study at 4 hospitals in India of 516 children under 5 years of age found that

157 43% had what was called "wheezy disease" consistent with asthma or bronchiolitis, neither
158 of which requires antibiotics.[8]

159 Because of the history of a high fatality rate from pneumonia in less developed countries,
160 especially prior to Streptococcus pneumonia and Haemophilus influnenzae immunizations, World
161 Health Organization guidelines had recommended empirical treatment with antibiotics, based on the
162 clinical presentation.[9] A placebo controlled clinical trial of amoxicillin in children who met the criteria
163 for that guideline was performed in 1126 Malawian children less than 6 years old.[10] Treatment failures
164 were 4 and 7 % in the amoxicillin and placebo group, respectively. No treatment failures by day 4
165 occurred in over 90% of the children, and there were no differences in the frequency of treatment
166 failures or relapses by day 14 in those without treatment failures by day 4. Thus, most of the patients
167 improved without antibiotics.[11] consistent with the relative infrequency of bacteria as a cause of
168 pneumonia seen in the U.S. Turkey, and India.[3,7,8]

169

170 **How to determine who to treat**

171 The question is not whether the child has pneumonia, as defined by radiologic imaging, but
172 does the child have a pneumonia due to bacterial infection. To identify those with bacterial pneumonia
173 from the majority with viral etiology, efforts have been made to examine the value of biomarkers,
174 white blood cell count and differential, C-reactive protein (CRP), and procalcitonin. Of those
175 inflammatory markers, C-reactive protein (CRP) values are significantly higher in the presence of
176 bacterial infection, but some degree of overlap has been seen.[12] There is general agreement that
177 procalcitonin is the most useful biomarker for identifying those with bacterial infection.[13]

178

Antibiotics therefore should be considered primarily after careful clinical assessment of how sick the child appears, the presence of fever, an elevated CRP, an elevated procalcitonin, and a radiologic image of a distinct lobar or lobular infiltrate. Fever and a toxic appearance may be the exception where antibiotics are appropriate without further initial assessment. While there also may be cases where the clinical and laboratory data are equivocal, the great majority of what has been called pneumonia does not justify more than supportive treatment without the use of antibiotics.

Summary

Pneumonia is a generic term for inflammation of the lung parenchyma with consolidation. Pneumonia may be acute or chronic, from various types of infectious or non-infectious causes or inflammation. Various respiratory diseases or abnormalities can be misdiagnosed as pneumonia. Few common acute pneumonias of children have bacterial infection. Overuse of antibiotics for "pneumonia" results from inadequate diagnostic consideration prior to a treatment decision. Identifying those patients with bacterial etiology of pneumonia is important because of the morbidity and occasional fatality that can occur from pyogenic bacterial pneumonia. A combination of clinical assessment, laboratory obtained biomarkers, and radiology can generally distinguish pneumonia with bacterial infection requiring antibiotic treatment from the majority that are viral and not likely to benefit from antibiotics.

199 **Table 1. Descriptive terminology for pneumonia. While these diagnoses may have**

200 **implications regarding the etiology, they lack the specific etiology that provides the best**

201 **option for treatment.**

202

By location	Epidemiological
bronchopneumonia	congenital
lobar	nosocomial
segmental	Community acquired
interstitial	Hospital acquired

203

204 **Table 2. Specific etiologic causes of pneumonia. Identifying the etiology of pneumonia**

205 **provides the most relevant information for determining treatment.**

206

Infections	Aspiration
viral	foreign body
bacterial	chronic aspiration
mycoplasma	acute hydrocarbon aspiration
chlamydia	
rickettsia	**Hypersensitivity**
fungal	allergic bronchopulmonary aspergillosis
protozoan	allergic alveolitis
spirochetal	

207

208

209 **Table 3. Pseudo-pneumonia – Areas of opacification on a chest film from consolidation**

210 **not from inflammation of the lung parenchyma may result in misdiagnosis as**

211 **pneumonia.**

Thymus	**Atelectasis**
Pulmonary sequestration	**Cystic adenomatoid malformation**
Bronchogenic cysts	**Neoplastic disease**
Lung agenesis	**Pulmonary hiemosiderosis**
Asthma	

212

213

214 **Figure 1.** The proportion of pathogens for each age group. RSV-respiratory syncytial virus;
215 HRV-Human rhinovirus; HMPV-human metapneumovirus; ADV-adenovirus; M pneumoniae-
216 Mycoplasma pneumoniae; PIV-parainfluenza virus; Flu-influenza A or B virus; CoV- corona
217 virus; S. pneumoniae-Streptococcus pneumoniae.[3] Reproduced with permission from Jain S et
218 al. N Engl J Med 2015;372:835-845.

219

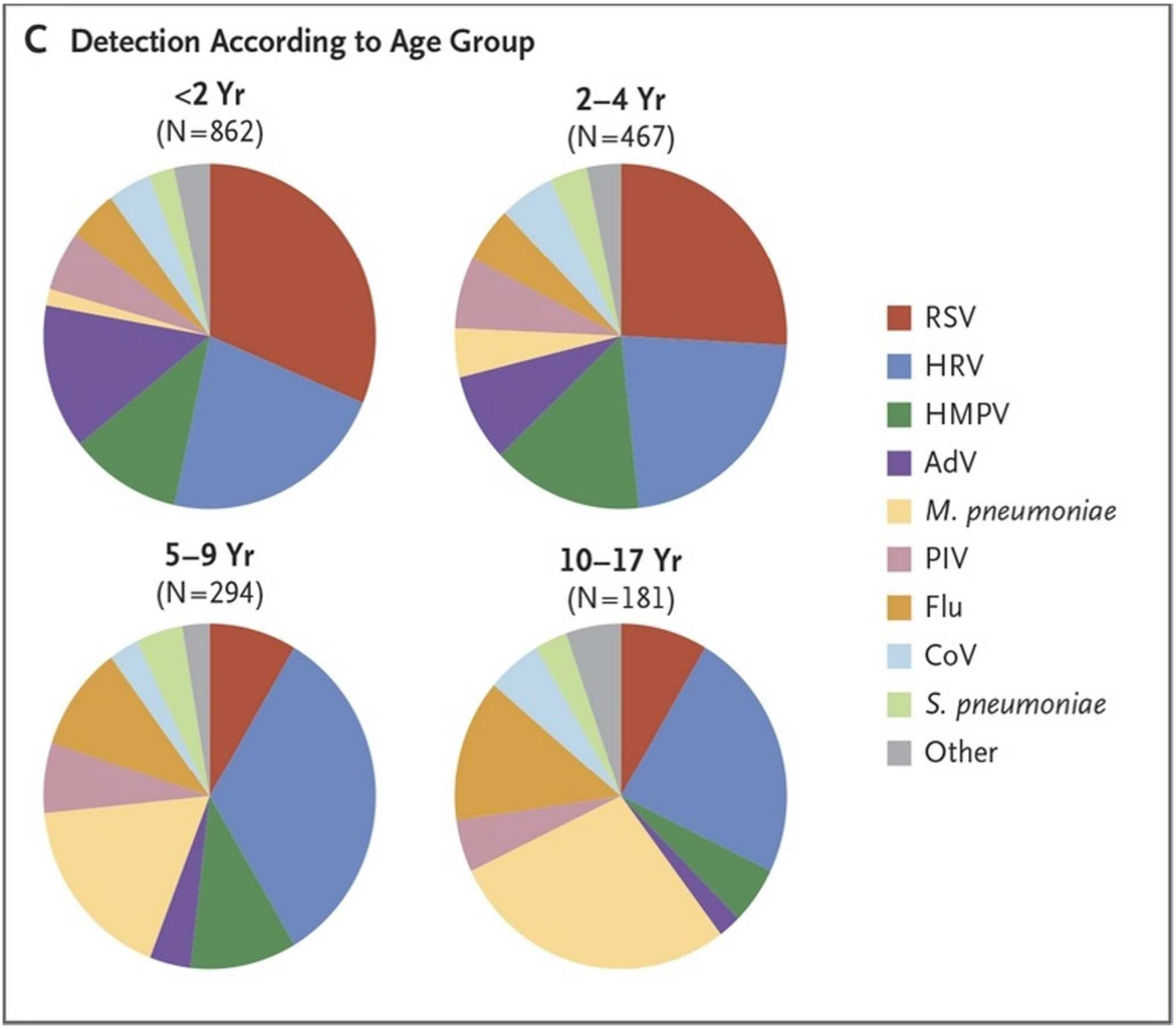

220

221

222

223

224 # References

[1] Stillerman A, Weinberger M, Smith W: Chronic interstitial pneumonitis in a 3-year-old from hypersensitivity to dove antigens. Pediatrics 1987;79:1027-9.

[2] Carr JL. Status thymico-lymphaticus. J Pediatr 1945;27:1-43.

[3] Jain S, Williams DJ, Arnold SR, Ampofo K, Bramley AN, Reed C, et al. Community-acquired pneumonia requiring hospitalization among U.S. children. N Engl J Med 2015;372:855-45.

[4] Ben Shimol S, Dagan R, Givon-Lavi N, Tal A, Aviram M, Bar-Ziv J, et al. Evaluation of the WHO criteria for chest radiographs for pneumonia diagnosis in children. Eur J Pediatr 2012;171:369-74.

[5] Elemraid MA, Muller M, SpencerDA, Rushton SP, Gorton R, Thomas MF, et al. Accuracy of the Interpretation of chest radiographs for the diagnosis of paediatric pneumonia. PLOS ONE 2014;9:e106051.

[6] Garber MD, Quinonez RA. Chest radiograph for childhood pneumonia: good, but not good enough. Pediatrics 2018;142(3):pii:e20182025.

[7] Anadol D Aydin YZ, Göçmen A. Overdiagnosis of pneumonia in children. Turk J Pediatr 2001;43:205-9.

[8] Gowraiah V, Awasthi S, Kapoor R, Sahana D, Venkatesh P, Gangadhar B, et al. Can we distinguish pneumonia from wheezy diseases in tachypneic children under low-resource conditions? A prospective observation study in four Indian hospitals. Arch Dis Child 2014;99:899-906.

[9] World Health Organization. Revised WHO classification and treatment of childhood pneumonia at health facilities: evidence summaries. http://apps.who.int/iris/bitstream/handle/10665/137319/9789241507813_eng.pdf;jsessionid=B07BA086A2FA7B8BF00F69DBA149AE86?sequence=1. Published 2014, accessed Dec 12, 2018.

[10] Ginsburg AS, Mvalo T, Nkwopara E, McCollum ED, Ndamala CB, Schmicker R, et al. Placebo vs amoxicillin for nonsevere fast-breathing pneumonia in Malawian children aged 2 to 59 months: a double-blind, randomized clinical noninferiority trial. JAMA Pediatr, Published online in advance of print, November 12, 2018.

[11] Driscoll AJ, Kotloff KL. Antibiotic treatment of nonsevere pneumonia with fast breathing – is the pendulum swinging? JAMA Pediatr. Published online in advance of print, November 12, 2018.

[12] Hoshina T, Nanisshi E, Kanno S, Nishio H, Kusuhara K, Hara T. The utility of biomarkers in differentiating bacterial from non-bacterial lower respiratory tract infection in hospitalized children: difference of the diagnostic performance between acute pneumonia and bronchitis. J Infect Chemother 2014;20: 616-20.

[13] Principi N, Esposito S. Biomarkers in pediatric community-acquired pneumonia. Int J Mol Sci 2017;18:pii:E447.